

# A Comparative Study of Potassium Hydroxide versus CO<sub>2</sub> Laser Vaporization in The Treatment of Female Genital Warts: A Controlled Clinical Trial

Nasrin Asadi<sup>1</sup>, MD; Ensie Hemmati<sup>2</sup>, MD; Golnaz Namazi<sup>2</sup>, MD; Mahnaz Pakniat Jahromi<sup>3</sup>, MD; Zahra Sarraf<sup>3</sup>, MD; Nader Pazyar<sup>4</sup>, MD; Alireza Salehi<sup>5</sup>, MD, MPH, PhD

<sup>1</sup>Maternal-fetal Medicine Research Center, Shiraz University of Medical Sciences, Shiraz, Iran;

<sup>2</sup>Department of Gynecology, Shiraz University of Medical Sciences, Shiraz, Iran;

<sup>3</sup>Department of Gynecologic Oncology, Shiraz University of Medical Sciences, Shiraz, Iran;

<sup>4</sup>Department of Dermatology, Ahvaz Jundishapur University of Medical Sciences, Ahvaz, Iran;

<sup>5</sup>Research Center for Traditional Medicine and History of Medicine, Department of Epidemiology, Shiraz University of Medical Sciences, Shiraz, Iran

**Corresponding author:**

Ensie Hemmati, MD; Department of Gynecology, Shahid Faghihi Hospital, Zand Street, Shiraz, Iran

**Tel/Fax:** +98 71 32332365; **Email:** drensie.hemmati@gmail.com

**Received:** 4 August 2015 **Revised:** 7 September 2015 **Accepted:** 10 September 2015

## ABSTRACT

**Background:** Genital warts are the most common viral sexually transmitted disease affecting 1% of the population. A prospective, open-label controlled trial was performed to compare topical 5% potassium hydroxide (KOH) solution with CO<sub>2</sub> laser in the treatment of female genital warts.

**Methods:** Seventy patients were enrolled in the study after convenience sampling. Right-sided lesions of the patients were treated by CO<sub>2</sub> laser every 3 weeks. The left-sided lesions of the same patients were treated by topical 5% KOH solution twice a day using a toothpick with cotton wrap on the tip. The patients were visited at 3, 6, and 9 weeks after initiation of the treatment and followed up for 6 months after the last visit.

**Results:** Out of seventy patients, sixty three completed the study and were analyzed. A total of 56 KOH treated-patients (88.9%) showed complete response. On the other hand, 56 laser-treated patients (88.9%) presented complete clearing of the lesion. There was not any difference in response to both modalities of treatment. Complications of KOH solution and CO<sub>2</sub> laser were 24% and 19% respectively ( $P>0.05$ ), but serious adverse events were not observed. The patients under KOH treatment displayed a recurrence rate of 11.1% (7 cases), while the same patients with CO<sub>2</sub> laser therapy demonstrated a recurrence rate of 7.9% (5 cases) ( $P=0.54$ ).

**Conclusion:** Topical 5% KOH solution was as effective as CO<sub>2</sub> laser in the treatment of female genital warts. There was not any serious complication in the application of KOH solution. This could be used as a new treatment for genital warts.

**Trial Registration Number:** IRCT201412207848N1

**KEYWORDS:** CO<sub>2</sub> laser; Genital warts; Potassium hydroxide; Therapeutics

**Please cite this article as:** Asadi N, Hemmati E, Namazi G, Pakniat Jahromi M, Sarraf Z, Pazyar N, Salehi AR. A Comparative Study of Potassium Hydroxide versus CO<sub>2</sub> Laser Vaporization in The Treatment of Female Genital Warts: A Controlled Clinical Trial. *IJCBNM*. 2016;4(3):274-282.

## INTRODUCTION

A review of the literature provides evidence that genital warts (condyloma acuminata) are the most common viral sexually transmitted disease affecting 1% of the population.<sup>1-6</sup> Genital warts may cause considerable impairments in patients' quality of life and sexual relationship.<sup>7,8</sup> They are highly contagious disease caused by human papillomavirus (HPV), predominantly HPV 6 and HPV 11.<sup>9-12</sup> HPV infection is a great burden on health care system.<sup>13,14</sup> The high rate of genital warts has been documented in adults between 18 and 28 years of age. According to a study in the United Kingdom (1996), about 10% of patients develop a persistent disease, with risk of benign proliferative lesions, high-grade precursors and finally invasive malignancies.<sup>3</sup>

Several treatment options are developed for eradication of genital warts including keratolytic agents, podophyllum, topical imiquimod, intraleison interferon alpha, 5-fluorouracil cream, cryosurgery, electrosurgery, and simple excisional surgery.<sup>15-18</sup> Although each of these treatment modalities is efficacious in some patients,<sup>19</sup> no single therapy stands out as uniformly effective<sup>20</sup> and most of the conventional therapies for female genital warts have high recurrence rates.<sup>21</sup>

Carbon dioxide (CO<sub>2</sub>) laser has been introduced to ablate the visible warts.<sup>22,23</sup> CO<sub>2</sub> lasers wavelength (10600 nm) is absorbed highly by water (primary chromophore for CO<sub>2</sub> laser). Alteration of radiant energy to heat directly elevates the temperature of the skin water to further than 100 °C; therefore, the tissue water vaporizes.<sup>24</sup> Also, CO<sub>2</sub> laser ablates and vaporizes the skin wart until normal tissue architecture is seen.<sup>23</sup> The spatial confinement of the laser light allows the exact tissue ablation resulting in fast healing with little or no scar tissue.<sup>25</sup>

Potassium hydroxide (KOH) is a potent alkali that has been found to be effective, safe, inexpensive, and well tolerated for the eradication of genital and plane warts as well

as *Molluscum contagiosum*. This results from the ability of KOH to dissolve keratin and its deep penetration into the skin.<sup>26-30</sup>

Based on an extensive search, a few studies have reported the therapeutic effect of topical KOH solution on genital warts. Also, the previous investigations have focused on the application of topical KOH solution in the treatment of male genital warts. In other words, there were not sufficient documents regarding the role of topical KOH solution in genital wart therapy and its application in the treatment of female genital wart. Therefore, according to prior reports of safety and high rate success with KOH solution for male genital wart therapy,<sup>27,31</sup> we conducted a study to compare the therapeutic effects of topical 5% KOH solution with CO<sub>2</sub> laser on the female external genital warts.

## MATERIALS AND METHODS

### Study Design

This open-label, controlled trial was performed to obtain a therapeutic option for the treatment of external genital warts in Motahari Clinic of Shiraz City, Southwest Iran, from March to August 2014.

### Study Population

According to the following formula, we calculated the sample size with an alpha error of 1% and a beta error of 10%, resulting in a 90% power.

n =

$$\frac{[z(\frac{\alpha}{2})\sqrt{2\pi(1-\pi)} + z(\beta)\sqrt{\pi_1(1-\pi_1) + \pi_2(1-\pi_2)}]^2}{\delta^2}$$

Seventy female patients in the age range of 15-55 years old with genital warts who had been diagnosed by a gynecologist were included in the study. Exclusion criteria were the patients with vaginal lesions, use of topical antiviral drugs during the past two weeks, pregnancy, lactation, and concurrent infection with other sexually transmitted diseases. We used convenience sampling to enroll the eligible patients.

### *Ethical Considerations*

This study was approved by Ethics Committee of Shiraz University of Medical Sciences. Before the study, each patient was consulted in detail and informed consent form was obtained.

### *Treatment Protocol*

#### *A) KOH Protocol*

A solution of 5% KOH was prepared by dissolving 5 g of KOH (Merck, Germany) in 100 ml of distilled water.<sup>31</sup> Each of the seventy patients received a 20 ml flask containing a 5% KOH aqueous solution. The left-sided lesions of the patients were treated by topical 5% KOH solution twice a day using a toothpick with cotton wrap on the tip. Then the patients were taught to apply KOH solution on the lesions. The solution was applied for up to 9 weeks. The response rate and complications were assessed at 3, 6, and 9 weeks after initiating the treatment. Subsequently, the patients were followed up for 6 months.

#### *B) CO<sub>2</sub> Laser Protocol*

After routine sterilization and local anesthetic application, the lesions and 2 mm surrounding the normal tissue were evaporated with CO<sub>2</sub> laser (Jeisys, South Korea and FDA approved). This laser had fractional mode with wavelength of 10600 nm and fluency of 5 J/cm<sup>2</sup>. Right-sided lesions of the seventy patients were treated by CO<sub>2</sub> laser every 3 weeks. Tetracycline ointment was applied on the area of the intervention. Laser therapy was done every 3 weeks up to 9 weeks depending on the response.

### *Outcome Measure*

An educated midwife measured the size of the lesions pre-treatment and post-treatment using a ruler. Response to the treatment was defined as bellow:<sup>32</sup> “complete response” as complete clearance of the warts, “excellent response” if there was 75-99% decrease in the size of the lesions, “good response” as a decrease up to 50-75% of the wart size, and “weak response” as a decrease under 50% in

the wart size.

### *Statistical Analyses*

Data analysis was performed using SPSS 18 and the results are presented as mean±SD. Chi-Square test, repeated measures ANOVA, and Fisher’s exact test were used. We used repeated measures ANOVA after checking Mauchly’s test of sphericity for comparison between various times. We used Pearson Chi-square test and Fisher exact test for univariate analysis in categorical variables. Also, a P value<0.05 was considered significant.

## **RESULTS**

A total of 70 female patients with genital warts and mean±SD age of 28.6±7.9 (age range: 15-50 years) were included in the study. Out of seventy patients, seven were dropped out the study because of non-complier and 63 patients completed it and were analyzed (Figure 1). No patient was dropped out because of adverse events of the treatments. Educational level of patients was followed as illiterate (4.3%), primary school (5.7%), middle school (8.6%), high school (11.4%), diploma (31.4%), bachelor degree and more (38.6%). According to marital status, 65.7% of the patients were married, 21.4% single, 7.1% divorced, and 5.7% widowed. The number of warts in each patient ranged from 1 to 40 (12.5±8.5). The duration of the lesions ranged from 1 to 12 months with a mean duration of 3.36±2.61 months. These lesions were located on the labia major, labia minor, fourchette, perinea, perianal, and mons pubis. The majority of the genital warts were on the labia major and the minority of them over the mons pubis. The size of the lesions ranged from 2-50 mm. The mean size of the lesions pre-treatment and post-treatment is shown in Table 1.

Response to topical KOH solution and CO<sub>2</sub> laser therapy at the end of the 3rd, 6th, and 9th weeks is shown in Table 2 and Figure 2. According to repeated measures ANOVA, the difference within the groups was significant (P<0.001), but the difference between them was not statistically significant (P=0.681).

CONSORT Flow Diagram

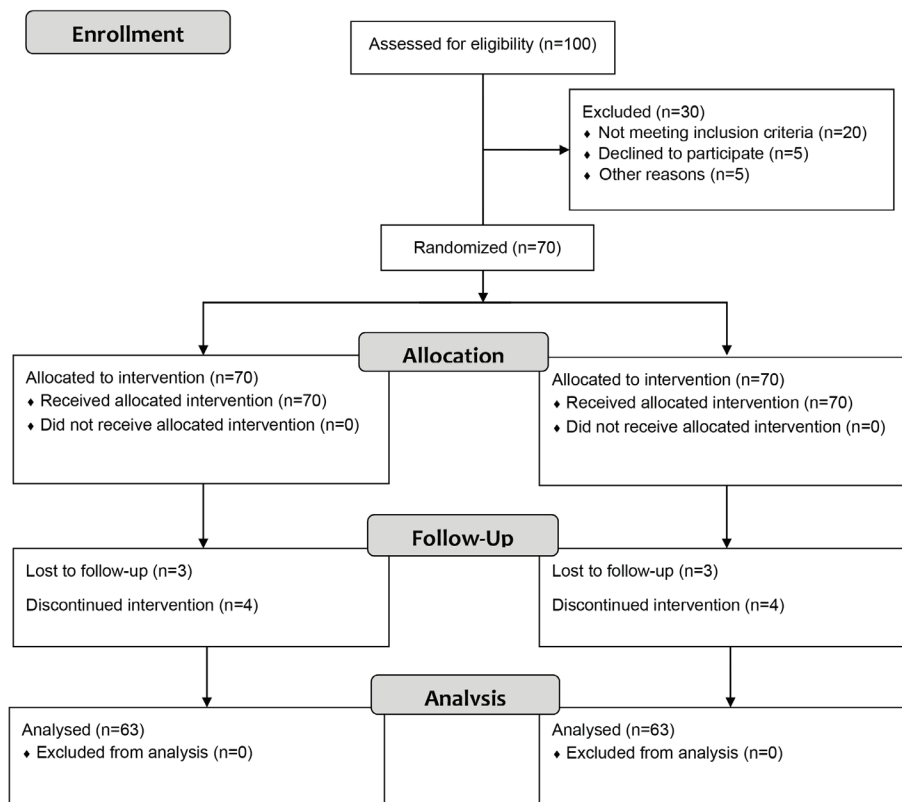


Figure 1: Design and protocol of the study

Table 1: The size of the lesions in pre-treatment and 3rd, 6th, and 9th weeks after the treatment

Time	Size of KOH treated lesions (mm) Mean±SD	Size of CO <sub>2</sub> laser treated lesions (mm) Mean±SD	P value
Pre-treatment	6.53±8.75	6.29±8.58	0.898
Post-treatment			
3rd weeks	2.09±6.04	1.24±5.29	0.371
6th weeks	1.14±5.65	0.88±5.11	0.791
9th weeks	1.43±6.13	0.90±5.12	0.601

Accordingly, the therapeutic effect of KOH solution and CO<sub>2</sub> laser was similar.

Most of the KOH and laser-treated patients (88.9%) showed complete clearing of lesions. Complications of KOH therapy were observed in 24% (15 cases) while those of laser intervention were seen in 19% (12 cases) of the same patients. Adverse events of KOH therapy included erythema 4 patients (6.34%), burn 7 (11.11%), erosion 9 (14.28%), and hyperpigmentation 2 (3.17%). Complications of laser therapy were erythema in 2 patients (3.17%),

burn in 2 (3.17%), erosion in 4 (6.34%), hypopigmentation in 2 (3.17%), and hyperpigmentation in 3 (4.76%). Fisher's exact test showed that the difference of complications between the two modalities was not statistically significant (P>0.05)

The patients under KOH treatment had a recurrence rate of 11.1% (7 cases), whereas the same patients with laser therapy had a recurrence rate of 7.9% (5 cases). There was not any significant difference in the recurrence rate between both modalities of treatment (P=0.54).

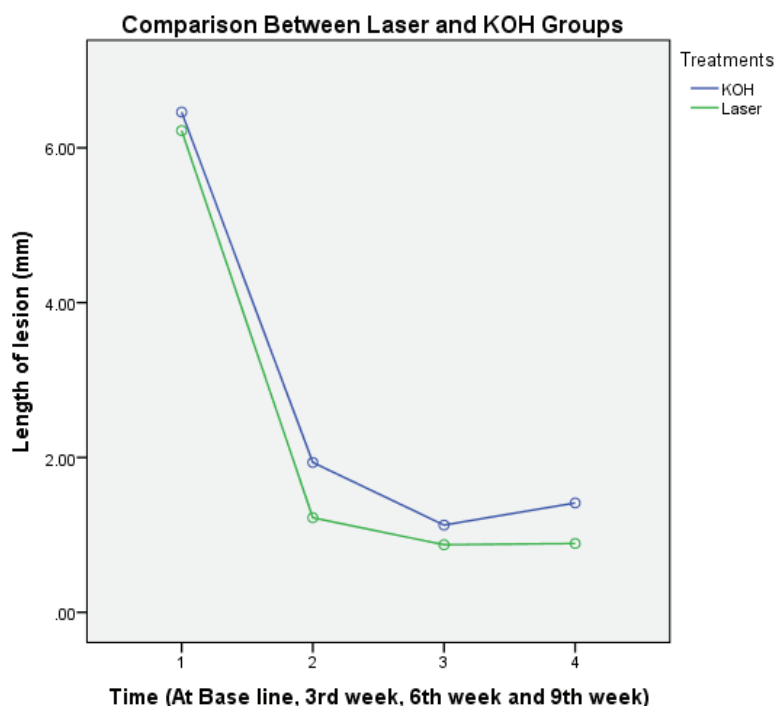


Figure 2: Comparison between KOH and laser therapy in the treatment of genital warts

Table 2: Response to treatment in the 3rd, 6th, and 9th weeks

Time after treatment	Completed Response	KOH Solution-N (%)	CO <sub>2</sub> Laser-N (%)	P value
3rd week	Yes	43 (64.2)	55 (82.1)	0.019
	No	24 (25.8)	12 (17.9)	
6th week	Yes	56 (87.5)	56 (87.5)	0.987
	No	8 (12.5)	8 (12.5)	
9th week	Yes	56 (88.9)	56 (88.9)	0.763
	No	7 (11.1)	7 (11.1)	

## DISCUSSION

Genital warts therapy is usually recommended based on the efficacy, adverse effects, cost and recurrence rates.<sup>25,33</sup> Various treatment modalities have been employed such as podophyllotoxin, salicylic acid, imiquimod, polyphenon E, 5-fluoracil, KOH, cryotherapy, electrosurgery, and laser.<sup>34-38</sup> Clearance rate of laser therapy has been reported 23-52% with recurrence rates of 60-77% for genital warts.<sup>17</sup>

In the current study, most of the KOH-treated patients (88.9%) showed complete clearing of the lesions. Also, most of laser-treated patients (88.9%) presented complete response. It means that, there was not any

difference between the two therapeutic modalities in clearing of visible genital warts. In other words, topical 5% KOH solution was as effective as CO<sub>2</sub> laser in the treatment of the lesions. The highest improvement of lesions in KOH and laser-treated patients was observed at the end of the 3rd week of treatment. This means that the most response was documented during 3 weeks after initiation of KOH and laser therapy. KOH solution complications were more than those of laser in the same patients and the difference was not considerable. KOH-treated lesions showed more erythema, burn, and erosion while laser-treated lesions presented more hyperpigmentation and



hypopigmentation. The results of the present study demonstrated that KOH solution had a higher rate of recurrence compared with CO<sub>2</sub>, but the difference was not prominent between the two treatment modalities. Our study showed that genital warts were more common in participants with higher education level and married patients. The most common complication of topical 5% KOH solution was erosion, while the least common one was post-treatment hypopigmentation. Another finding of the current study demonstrated that labia major were the most common location for developing genital warts.

According to the medical literature, there were a few clinical researches describing the positive therapeutic role of KOH in the treatment of genital warts. Some investigators evaluated topical 5% KOH solution in male patients with genital warts. They included 35 men in their study. The patients were evaluated for 3 months and the last month was dedicated to the recurrence monitoring. They documented that 87.5% of the patients had complete clearing of the lesions.<sup>31</sup>

Some researchers compared topical 5% KOH solution with liquid nitrogen (cryotherapy) in 36 men with genital warts for 8 weeks. The patients were followed up for 2 months to determine the recurrence rate. This trial revealed that 84.6% of the patients were improved with KOH therapy without any recurrence, but the patients treated with cryotherapy had recurrence.<sup>27</sup>

Another randomized controlled trial was conducted to assess the therapeutic effect of topical 5% KOH solution vs. cryotherapy on the genital warts of sexually active men. A total of 48 patients were enrolled in the study during a period of 10 months and followed up for 1 month. At the end of the trial, 54.2% of the patients treated with KOH were completely wart-free without recurrence. Superficial erosions, burning, and hypopigmentation were observed in the patients. This study demonstrated that 5% KOH solution was at least as effective as cryotherapy for the treatment of male genital warts.<sup>26</sup>

It is likely that the action mechanism of KOH is related to its keratolytic role leading to the destruction of the contaminated cells and induction of inflammation.<sup>28</sup>

To the best of our knowledge, the present study was the first controlled trial that examined the therapeutic effect of KOH solution on female genital warts. The previous studies were conducted on 35-48 men with genital warts. In the prior studies, complete response rate of KOH therapy was reported 54.2-87.5% and the duration of follow-up was 1-3 months.<sup>26,27,31</sup> Our findings were consistent with three previous studies and complete response was observed in most patients under treatment with KOH 5% solution.<sup>26,27,31</sup> Our study, compared with that of Camargo *et al.*,<sup>26</sup> presented more complete response with KOH therapy and less adverse events including burning, erosion, and hyperpigmentation.

It is probable that the higher rate of complete response in our study results from the bigger sample size. The present investigation compared with the previous trials had three advantages. Firstly, it was performed with larger sample size. Secondly, the patients were followed up for the longer period. Third, the current study was self-controlled and possible confounders such as genetic and environmental factors were controlled.

The most remarkable superiority of KOH over CO<sub>2</sub> laser therapy is that KOH solution is applied by the patients and considered cost-benefit for both patients and healthcare system. On the other hand, CO<sub>2</sub> laser therapy is operator dependent, expensive, time consuming, and needs several separate treatment cycles. Our findings regarding topical KOH application proved promising effects of this agent in treatment of external genital warts. This new treatment modality should be more considered because it is effective, safe, and low cost agent applied by the patients.

The present trial had some limitations. We conducted this study in a single center while performing in a multicenter would help to more strengthen the clinical research. In

addition, we excluded the pregnant women with genital warts from the study because we had not any document related to safety of KOH solution application in these patients.

## CONCLUSION

Our findings confirmed previous studies regarding the therapeutic role of topical KOH solution on genital warts. The present trial showed that topical 5% KOH was as effective as CO<sub>2</sub> laser on the improvement of female genital warts. There was not any serious complication in the application of KOH solution. This chemical agent can be included as a new therapeutic modality in the spectrum of therapies for genital warts. Though KOH therapy seems to be quite effective, further randomized control trials will provide more evidence of the effectiveness of this novel agent. Various concentrations of KOH solution such as KOH 2.5% and 10% can be investigated in the future clinical studies. Evaluation of the efficacy and complications of KOH solution in pregnant animals can be done prior to its use in pregnant women with genital warts.

## ACKNOWLEDGMENT

The present article was extracted from the thesis written by Dr. Ensie Hemmati (Grant No: 92-01-01-6325) and financially supported by Shiraz University of Medical Sciences.

**Conflict of Interest:** None declared.

## REFERENCES

- 1 Gross G. Genitoanal human papillomavirus infection and associated neoplasias. *Curr Probl Dermatol.* 2014;45:98-122.
- 2 Paba P, Morosetti G, Criscuolo AA, et al. Prevalence of human papillomavirus infection in Italian and immigrant women. *Int J Immunopathol Pharmacol.* 2012;25:1055-62.
- 3 Niazy F, Rostami K, Motabar AR. Giant condyloma acuminatum of vulva

- frustrating treatment challenge. *World J Plast Surg.* 2015;4:159-62.
- 4 Salavastru CM, Niculescu MC, Zota A, et al. Epidemiological aspects of genital warts in Romania - a 2012 retrospective survey. *Maedica (Buchar).* 2014;9:144-50.
- 5 Gormley RH, Kovarik CL. Human papillomavirus-related genital disease in the immunocompromised host: Part I. *J Am Acad Dermatol.* 2012;66:867.e1-14;quiz881-2.
- 6 Bhatia N, Lynde C, Vender R, Bourcier M. Understanding genital warts: epidemiology, pathogenesis, and burden of disease of human papillomavirus. *J Cutan Med Surg.* 2013;17:S47-54.
- 7 Mortensen GL, Larsen HK. The quality of life of patients with genital warts: a qualitative study. *BMC Public Health.* 2010;10:113.
- 8 Gupta AK, Daigle D. Sinecatechins 10% ointment: a green tea extract for the treatment of external genital warts. *Skin Therapy Lett.* 2015;20:6-8.
- 9 Tatti S, Stockfleth E, Beutner KR, et al. Polyphenon E: A new treatment for external anogenital warts. *Br J Dermatol.* 2010;162:176-84.
- 10 Friedman M, Bayer I, Letko I, et al. Topical treatment for human papillomavirus-associated genital warts in humans with the novel tellurium immunomodulator AS101: assessment of its safety and efficacy. *Br J Dermatol.* 2009;160:403-8.
- 11 Anic GM, Giuliano AR. Genital HPV infection and related lesions in men. *Prev Med.* 2011;53:S36-41.
- 12 Patel H, Wagner M, Singhal P, Kothari S. Systematic review of the incidence and prevalence of genital warts. *BMC Infect Dis.* 2013;13:39.
- 13 Centers for Disease Control and Prevention (CDC). Recommendations on the use of quadrivalent human papillomavirus vaccine in males--Advisory Committee on Immunization Practices (ACIP), 2011. *Morb Mortal Wkly Rep.* 2011;60:1705-8.
- 14 Weinstock H, Berman S, Cates W Jr.

- Sexually transmitted diseases among American youth: incidence and prevalence estimates, 2000. *Perspect Sex Reprod Health.* 2004;36:6-10.
- 15 Tzellos TG, Sardeli C, Lallas A, et al. Efficacy, safety and tolerability of green tea catechins in the treatment of external anogenital warts: A systematic review and meta-analysis. *J Eur Acad Dermatol Venereol.* 2011;25:345-53.
  - 16 Workowski KA, Bolan GA; Centers for Disease Control and Prevention. Sexually transmitted diseases treatment guidelines, 2015. *MMWR Recomm Rep.* 2015;64:1-137.
  - 17 Scheinfeld N, Lehman DS. An evidence-based review of medical and surgical treatments of genital warts. *Dermatol Online J.* 2006;12:5.
  - 18 Saiag P, Bauhofer A, Bouscarat F, et al. Imiquimod 5% cream for external genital or perianal warts in human immunodeficiency virus-positive patients treated with highly active antiretroviral therapy: an open-label, noncomparative study. *Br J Dermatol.* 2009;161:904-9.
  - 19 Meltzer SM, Monk BJ, Tewari KS. Green tea catechins for treatment of external genital warts. *Am J Obstet Gynecol.* 2009;200:233.e1-7.
  - 20 Zedan H, Hofny ER, Ismail SA. Propolis as an alternative treatment for cutaneous warts. *Int J Dermatol.* 2009;48:1246-9.
  - 21 Chen K, Chang BZ, Ju M, et al. Comparative study of photodynamic therapy vs. CO<sub>2</sub> laser vaporization in treatment of condylomata acuminata: A randomized clinical trial. *Br J Dermatol.* 2007;156:516-20.
  - 22 Shi H, Zhang X, Ma C, et al. Clinical analysis of five methods used to treat condylomata acuminata. *Dermatology.* 2013;227:338-45.
  - 23 Oni G, Mahaffey PJ. Treatment of recalcitrant warts with the carbon dioxide laser using an excision technique. *J Cosmet Laser Ther.* 2011;13:231-6.
  - 24 Janik JP, Markus JL, Al-Dujaili Z, et al. Laser resurfacing. *Semin Plast Surg.* 2007;21:139-46.
  - 25 Yanofsky VR, Patel RV, Goldenberg G. Genital warts: a comprehensive review. *J Clin Aesthet Dermatol.* 2012;5:25-36.
  - 26 Camargo CL, Belda Junior W, Fagundes LJ, Romiti R. A prospective, open, comparative study of 5% potassium hydroxide solution versus cryotherapy in the treatment of genital warts in men. *An Bras Dermatol.* 2014;89:236-40.
  - 27 Yaghoobi R, Jalal Lotfi S, Pazyar N, Kazerouni A. Comparison of efficacy of 5% potassium hydroxide solution versus cryotherapy in the treatment of male genital wart: A randomized clinical trial. *G Ital Dermatol Venereol.* 2014;149:149-50.
  - 28 Al-Hamdi KI, Al-Rahmani MA. Evaluation of topical potassium hydroxide solution for treatment of plane warts. *Indian J Dermatol.* 2012;57:38-41.
  - 29 Işık S, Koca R, Sarici G, Altinyazar HC. A comparison of a 5% potassium hydroxide solution with a 5-fluorouracil and salicylic acid combination in the treatment of patients with anogenital warts: A randomized, open-label clinical trial. *Int J Dermatol.* 2014;53:1145-50.
  - 30 Romiti R, Ribeiro AP, Romiti N. Evaluation of the effectiveness of 5% potassium hydroxide for the treatment of molluscum contagiosum. *Pediatr Dermatol.* 2000;17:495.
  - 31 Loureiro WR, Cação FM, Belda W Jr, et al. Treatment of genital warts in men with potassium hydroxide. *Br J Dermatol.* 2008;158:180-1.
  - 32 Akhyani M, Ehsani AH, Noormohammadpour P, et al. Comparing pulsed-dye laser with cryotherapy in the treatment of common warts. *J Lasers Med Sci.* 2010;1:14-9.
  - 33 Fox PA, Tung MY. Human papillomavirus: burden of illness and treatment cost considerations. *Am J Clin Dermatol.* 2005;6:365-81.
  - 34 Vender R, Bourcier M, Bhatia N, Lynde C. Therapeutic options for external genital warts. *J Cutan Med Surg.* 2013;17:S61-7.



- 35 Grillo-Ardila CF, Angel-Müller E, Salazar-Díaz LC, et al. Imiquimod for anogenital warts in non-immunocompromised adults. *Cochrane Database Syst Rev.* 2014;11:CD010389.
- 36 Stern PL, van der Burg SH, Hampson IN, et al. Therapy of human papillomavirus-related disease. *Vaccine.* 2012;30:F71-82.
- 37 Stockfleth E, Beti H, Orasan R, et al. Topical Polyphenon E in the treatment of external genital and perianal warts: a randomized controlled trial. *Br J Dermatol.* 2008;158:1329-38.
- 38 Gilson RJ, Ross J, Maw R, et al. A multicentre, randomised, double-blind, placebo controlled study of cryotherapy versus cryotherapy and podophyllotoxin cream as treatment for external anogenital warts. *Sex Transm Infect.* 2009;85:514-9.